

PATIENT

Smokey Uliano

SPECIES

Feline

BREED

DLH

SEX

Male Neutered

AGE

14 years

WEIGHT

8.4lbs

INTERPRETED BY

Maggie Machen Lamy,
DVM, DACVIM
(Cardiology)

IMAGING PERFORMED BY

Hougentogler, DVM

HOSPITAL NAME

K-Vet Animal Care

REFERRING VET

Dr. Konegger

INVOICE

46654

DATE

2/2/26

PRESENTING CLINICAL SIGNS

History: Recheck echo - history of cardiomyopathy (a prior report is not provided for comparison). BNP: 186. BP: 200, 220mmHg. On Enalapril 1.25mg, q24h and Clopidogrel 18.75mg q24h. 6/2024 Idexx: ECG normal with tall R waves. CXR showed cardiomegaly and an echocardiogram was recommended.

ECHOCARDIOGRAM FINDINGS

2D, m-mode, color flow and doppler imaging is available. The left ventricular wall is mildly increased in dimension. There is a mildly hyperechoic endocardium consistent with fibrosis. Mild symmetric papillary muscle hypertrophy and remodeling. The right ventricle is subjectively normal in size and morphology. There is no left atrial enlargement present. No right atrial enlargement present. Normal RVOT velocity. Trace TR. Normal LVOT velocity. There is no obvious systolic anterior motion (SAM) of the mitral valve present. No MR. Trace AI. No PI. There is no pericardial effusion noted. No pleural effusion appreciated. No obvious cardiac tumors.

CARDIAC CHART

FELINE CARDIAC PARAMETERS	BODY WEIGHT (kg)	HR (BPM)	IVSd (cm) (Moise, Pipers)	LVIDd (cm) (Moise, Pipers)	LVWd (cm) (Moise, Pipers)	FS (%)	EF (%)
NORMAL PARAMETER	-----	150-240	0.35-0.55	<2 (mean 1.5)	3.5-0.55	35-67	80-100
PATIENT	3.8	NM	0.63	1.3	0.61	46	81
FELINE CARDIAC PARAMETERS	LA/AO (Boon)	LA/AO HEART BASE (Swe) (Abbott)	LA 2D short axis Base view (cm) (Abbott)		LVOT VEL (m/s)	RVOT VEL (m/s)	E max (m/s)
NORMAL	<1.5	<1.3	<1.2		<1.6	<1.3	<0.9
PATIENT	NM	1.3	1.3		1.0	1.3	NM
<p><i>*Note: All measurements based upon multi-modal images and methods. An average value is reported.</i> Adapted from June Boon, Veterinary Echocardiography, 1998 Abbott J & MacLean H JVIM 2006;20: 111-119, Moise et al. Am J Vet Res 47:1476, 1986. Pipers et al. Am J Vet Res 40:882, 1979.</p>							

INTERPRETATION OF THE FINDINGS & FURTHER RECOMMENDATIONS

Hypertrophic cardiomyopathy (HCM) is a rule out diagnosis once a patient is deemed normotensive and euthyroid. Both should be ruled out in this case as contributing factors. The degree of disease is mild, with only mild LVH and no LA dilation. This would indicate the risk for clinical issues is low at this time. Flow through the great vessels is normal, and no significant valve regurgitation is seen. No additional pathology is identified. Without a prior report, it is unclear whether these changes are stable or if this is the first echocardiogram.

Given these findings, no medications are indicated. Plavix is only necessary if there is significant left atrial enlargement, which is not appreciated here. Additionally, use of an ACE-I should be dictated by prior BP readings. The reported BP in this case is currently elevated. If thought to be an accurate reading, more aggressive vasodilator therapy with Amlodipine may be necessary. This differentiation should be dictated by IM, and screening for causes of SHT should also be considered.



PATIENT

Smokey Uliano

SPECIES

Feline

BREED

DLH

SEX

Male Neutered

AGE

14 years

WEIGHT

8.4lbs

INTERPRETED BY

Maggie Machen Lamy,
DVM, DACVIM
(Cardiology)

IMAGING PERFORMED BY

Hougentogler, DVM

HOSPITAL NAME

K-Vet Animal Care

REFERRING VET

Dr. Konegger

INVOICE

46654

DATE

2/2/26

It is important to note that no medications have been shown to definitively alter long term outcome at this stage, particularly in the absence of SAM. *Regarding the newly available drug Felycin-CA1:* Recent data reports that Felycin-CA1 may improve the degree of LV hypertrophy in some cats with naturally occurring subclinical HCM. The clinical benefit is currently unknown and is still being investigated. The HALT trial is actively enrolling HCM cats all over the US in order to acquire prospective data on a larger sample size of cats. Should you wish to use the medication, the published dose is 0.3mg/kg weekly, and the drug should be avoided in cats with advanced cardiac changes, diabetes, non-healing wounds, active infections or liver disease. The medication is an immunosuppressant and should be used with caution. For further information, please visit www.triviumvet.com.

Long term prognosis is guarded for subclinical HCM, with a great deal of variability in rate of progression. The REVEAL study showed that approximately 7% of asymptomatic cats with HCM will develop CHF or a cardiogenic thrombus within 1 year, 20% within 5 years, and ~30% within 10 years. Close monitoring for progressive LA dilation going forward will help better predict long term outcome.

Monitor at home for any respiratory issues or signs of blood clot events (neurologic change, paralysis, etc.).

Anesthetic risk is considered mildly elevated; however, judicious fluid administration is advised if needed with careful monitoring to screen for fluid overload. A reasonable protocol includes opioid/benzodiazepine premedication, propofol induction, isoflurane maintenance. Avoid ketamine, telazol, acepromazine and Dexdomitor. Additionally, drugs that stimulate heart rate should be avoided unless clinically necessary (glycopyrrolate, atropine).

Risk for complication with steroid or fluid use typically follows LA dilation, which in this case is mildly elevated. If needed, monitoring of RR/RE is advised particularly in the initiation phase.

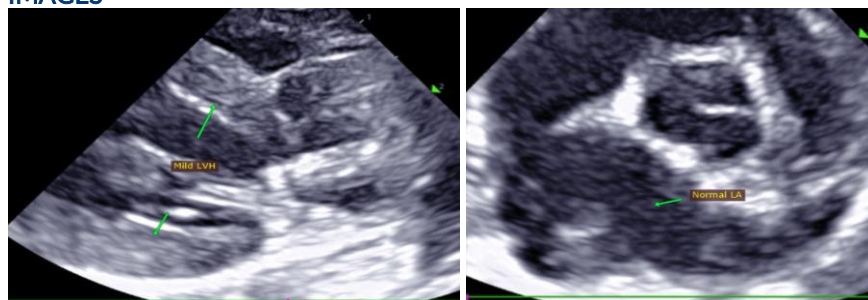
PLAN

Plavix and Benazepril are not clearly indicated in this case. Reassess BP and treat if indicated.

A screening blood pressure and T4 are recommended every 6 months lifelong.

A recheck echocardiogram is recommended in 6 months to assess for progression, sooner if any issues arise in the interim.

IMAGES





PATIENT

Smokey Uliano

The information and recommendations provided are based on the images presented by the referring veterinarian. No evaluation can be communicated regarding pathology that was not visible in the image/video clips provided.

SPECIES

Feline

Thank you for this referral. This report was generated using transcription software, and minor dictation errors may be present. If the clinical or image interpretation does not parallel your findings or if I can be of any further assistance, please contact me.

BREED

DLH

Maggie Machen Lamy, DVM
Diplomate of the American College of Veterinary Internal Medicine (Cardiology)
info@sonopath.com

SEX

Male Neutered

AGE

14 years

WEIGHT

8.4lbs

INTERPRETED BY

Maggie Machen Lamy,
DVM, DACVIM
(Cardiology)

IMAGING PERFORMED BY

Hougentogler, DVM

HOSPITAL NAME

K-Vet Animal Care

REFERRING VET

Dr. Konegger

INVOICE

46654

DATE

2/2/26